

Animal Sciences

Hoof Anatomy, Care and Management in Livestock

Kate Hepworth, Animal Sciences Student; Dr. Michael Neary, Extension Animal Scientist; Dr. Simon Kenyon, Extension Veterinarian.

Introduction

The hoof is an extremely important structure in an animal's body. Although an animal with hoof problems may be able to function, chances are that optimal animal production and performance will be reduced depending upon the severity of the problem.

A cow with painful feet is less likely to walk, and therefore, less likely to have the desire to get to a feed bunk, which will reduce weight gain or milk production compared to that of an animal able to consume its full ration of feed every day. Although some hoof problems are unavoidable, sound hoof management procedures can greatly reduce the incidence of hoof problems in all types of animals. A good hoof care program leads to lowered expenses in treatment of problems, as well as fewer losses due to decreased performance and productivity of the animal.

Although the structure of the hoof differs from species to species, the basic anatomy is very similar between species. In order to understand how to properly care for the hoof, it is important that an owner understand the basic structure and anatomy of the hoof. In this publication, a bovine foot will be used to illustrate the general anatomy of a typical hoof.

Anatomy

Cattle, sheep, goats, and pigs are cloven-footed animals, meaning that the hoof consists of two digits, instead of one solid entity like that of a horse. The two digits are analogous to the third and fourth fingers of the human hand. The claws are named by their relative location on the foot. There is the outer, or lateral claw, and the inner, or medial claw. In cattle, the lateral claw is slightly

larger in the back feet, while the medial claw is the larger claw in the front feet. The space between the two claws is called the interdigital cleft; the area of skin is called the interdigital skin. The different surfaces of the claws are named according to their relative position to the interdigital cleft: the abaxial surface is the outer wall of each claw, and the axial surface is the inner wall.

The hoof is described from the outside moving in, beginning with the hard outer covering of the hoof, known as the hoof wall, or horn (See **Figure 1**). The horn is a hard surface, structurally similar to the human fingernail, but functionally like the epidermis of the skin. The cells that form the horn are produced by the tissue directly beneath the hoof wall, called the corium, at the hoof head. The corium is a nutrient-rich tissue that contains many

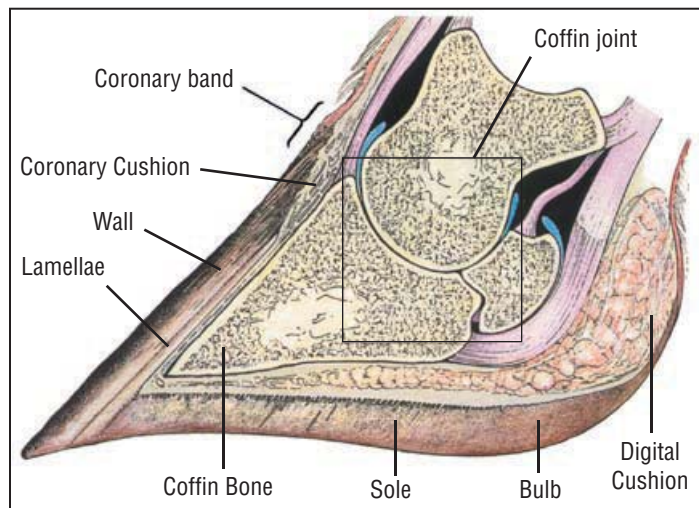


Figure 1. Bovine hoof

Picture courtesy of Cattle Footcare and Claw Trimming, by the late E. Toussaint Raven.

important blood vessels and nerves inside the hoof. The corium is similar to the quick of the fingernail in humans in that it continuously produces new cells that are then gradually pushed away from the quick. As the cells are pushed away from the corium, they die and produce the hard, new outer growth that we see both in our own nails and in hoof growth. At this point the cells are said to have been keratinized, or cornified. The new growth comes out at the coronary band, the point where the hoof meets the hairy skin on the animal's foot. The soft, new hoof growth that has just come to the surface is referred to as the periople and is shiny and holds in the moisture of the hoof. As can be seen in the rings that often occur on an animal's hooves, horn is produced at varying rates, because of variation in factors such as nutrition, health, and living conditions. However, as a general rule, bovine hooves grow about 1/5 to 1/4 of an inch per month and horse's hooves grow in general 1/4 to 3/8 of an inch per month.

Underneath the hoof is a slightly softer region, called the sole. The tissue that makes up the sole is produced by the corium of the sole, and is suppler than the horn of the hoof wall. The point where the hoof wall is bound to the sole is called the white line. The white line is a somewhat flexible junction between the sole and wall, allowing the hoof to be more flexible as the animal moves. The front region of the sole is called the toe, and the two bulbs at the opposite end of the foot are referred to as the heel bulbs.

Inside the hoof, there are bones that play a key role not only in forming the shape of the hoof, but also in serving as a support structure for the leg and the rest of the body (**See Figure 2**). The sole should be from five to seven millimeters thick for the inside of the hoof to be protected properly. Directly above the sole is the corium, which is below the digital cushion. The digital cushion is a pad of fatty tissue that serves to protect the corium, as well as to aid in blood transport in the leg. It also serves as a shock absorber for the digital phalange bones. The pedal bone is directly above the digital cushion and is the largest bone in the hoof. The pedal bones provide the framework for the general shape of each claw, and they are key components in the movement of the animal. The pedal bone is attached to the corium by sensitive connective tissue called the laminar tissue, or laminae. The laminae holds the animal suspended in its hoof. The deep flexor tendon is attached to the back portion of the pedal bone, making it very important for locomotion and flexion of the foot. The short pastern bones (P2) snugly fits into the top of the pedal bone, forming a condular joint referred to as the pedal joint. Seated directly behind the pedal joint is a small bone called the distal sesamoid bone (navicular bone), which serves as a fulcrum for the movement of the joint. The long pastern bone (P1) then fits into the top of the short

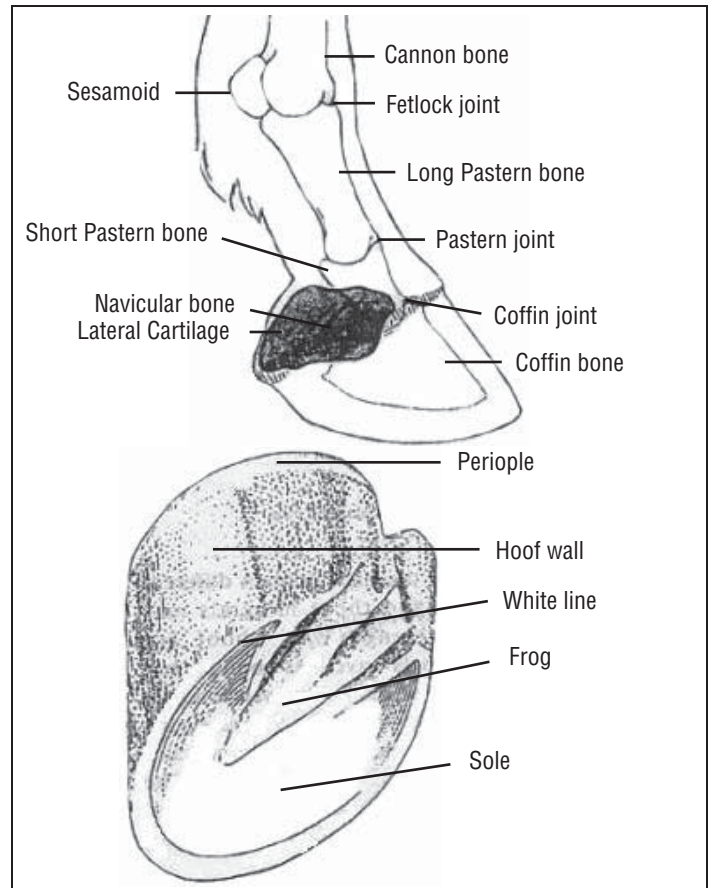


Figure 2. Equine hoof *interior* (top) and **Figure 3.** Outer anatomy of an equine hoof

pastern bone, forming the pastern joint. Above the long pastern bone is the fetlock joint and above that the cannon bone of the lower leg. The pedal bone is the only bone of these three that is completely inside the actual hoof, while the pastern bones serve to connect the hoof to the rest of the leg.

The bones in the hoof do not entirely formulate the movement of the foot and the leg. Several tendons allow the animal its range of motion. For example, the deep flexor tendon attaches to the pedal bone and goes up the back of the leg, allowing the animal to flex its foot; the extensor tendons in front allow the animal to pick up its foot and move it forward. Directly below the flexor tendon is the digital cushion, which aids in pumping blood throughout the foot and up the rest of the leg as well as serving as a shock absorber to protect the sensitive tissues from the bones of the hoof.

The structure of the equine foot is very similar to the cloven-footed hoof anatomy described above, but there are a few differences (**See Figures 2 and 3**). First and foremost, the hoof of the horse consists of one continuous structure. The outer wall is the same as that of a cow or sheep; however, the sole is slightly different. In the middle of a horse's sole is a V-shaped cleft, called the frog. The

frog serves as a cushy, weight bearing surface that absorbs shock and aids in pumping blood throughout the hoof and up the leg. On either side of the V there are deep clefts, followed by ridges called the bars. The bars are a continuation of the hoof wall from the heel. The general bone structure of a horse's hoof is like that of a cow, except that the horse only has one set of bones, as opposed to the two claws of a bovine hoof. The main difference is not in the structure, but the name of the pedal bone. The third phalange is called the pedal bone in most animals but is often known as the coffin bone in the equine hoof; however, despite the difference in name, the function is the same.

Maintenance

After the anatomy of the hoof is understood, it is much easier to comprehend how certain lamenesses occur, how to prevent them, and how and why one should keep feet in good, working condition. As many veterinarians and livestock producers will note, a well-maintained routine of cleaning and trimming animals' feet will lead to a far lower incidence of discomfort and lameness in the animals.

Nutrition also plays a key role in hoof health and maintaining proper growth rate. By keeping an animal well fed with the proper nutrients such as zinc and biotin, it is much more likely that they will produce good-quality hoof horn and have stronger feet. Different species require different amounts of routine hoof management practices to keep them in healthy condition. Cattle, horses, sheep, and goats do not require extensive trimming if the hoof remains balanced and wears down evenly on all walls of the hoof. The most important practice in caring for the hooves of any species is regular trimming of the hoof, which restores the natural shape of the hoof and keeps the bearing surfaces correctly proportioned. Since the horse is valued as an athlete for its quality of movement, as opposed to being a food source, it may require additional hoof care and maintenance.

Trimming schedules can depend on a variety of factors. For example, animals that are kept in pasture are less likely to develop painful foot problems than those living on hard cement. Although one may think that animals kept on cement may wear down their feet more quickly, their hooves still need to be trimmed frequently because the hard cement is many times more uncomfortable for a misshapen hoof than pasture. In addition, the rough surface of the cement can cause more blood flow to the hoof and increase the growth rate of the hoof tissue. It is a general recommendation that a dairy cow's hooves are checked and trimmed (if needed) twice a year. Many dairy producers choose to go through their herd every six months, or so, and trim only the animals that appear lame or have overgrown hooves. The general rule for equine hooves is that they should be trimmed every six to eight

weeks. Again, this can differ from animal to animal, as well as from season to season. Many horses' feet tend to grow faster in the summer when pasture is abundant. Horses are also shod, which slows the wearing of the hoof wall. Sheep and goats may be trimmed from once to twice yearly, although this largely depends on the conditions they are raised in and any health issues of the hoof (See **Figure 4**). All animals kept in rocky conditions may not need their hooves trimmed at all because the hard surface will wear their feet down naturally. However, sheep and goats kept on softer surfaces should be evaluated periodically for overgrowth.



Photo courtesy of Fias Co Farms

Figure 4. Newly trimmed goat hoof

Most food animals require basic hoof evaluation and possible maintenance a few times a year to keep their feet in good condition. Horses, however, are primarily used for riding or driving, which puts a lot of stress on their feet, leading to the need for added support and maintenance of their feet. This support and protection can come in the form of a horse shoe. Shoes serve as a mechanism to protect the hoof wall from excessive wear, and they keep the proper weight distribution of the hoof, while raising the more delicate parts of the hoof off of the ground to protect it from any injuries that may come during exercise. The shoe is nailed or glued onto the hoof around the outer rim of the wall. There is a wide variety of shoe types available, and the decision as to which is best for a particular animal depends on the amount and type of work a horse does and the surface on which the animal works. Although shoes are not necessary for most horses, they are needed and can be beneficial when fitted correctly and properly maintained.

Regardless of whether or not an animal is shod, the animal needs to have its hooves cleaned regularly. Cleaning the hooves requires a tool called a hoof pick. It is used in a toe-to-heel action to dig out the matter that has built up on the sole, under the shoe, and especially in the clefts of the frog. This is also a good time to inspect

the hoof and sole for any foreign objects that may have penetrated the hoof, for discoloration or discharges, and to make sure that the shoes are on securely.

As mentioned earlier, hooves grow at different rates, depending on a variety of factors. It is important that owners become familiar with the rate of growth of their animals' feet, not only so that they can keep them trimmed, but so that they are attentive to any changes in the rate of growth, which could be an indication of a serious problem. As a general rule, equine hooves grow about $\frac{1}{4}$ to $\frac{3}{8}$ of an inch per month, and bovine hooves grow about $\frac{1}{5}$ to $\frac{1}{4}$ of an inch of new growth every month. Any hoof overgrowth can cause discomfort to the animal. The bones in the hoof are meant to sit squarely inside the hoof, at an approximately 50 degree angle to the ground. When hooves become too long, the weight-bearing surfaces of the hoof can be changed and unbalanced, and the bones can begin to splay inside the foot (**See Figure 5**). The key weight-bearing surfaces of the hoof should be the outer edge of the hoof wall, the outer parts of the sole, and a portion of the heel. The main goal of trimming hooves is to restore the natural shape of the hoof so that weight is distributed evenly and in a manner that is best for all structures of the hoof and the comfort of the animal.

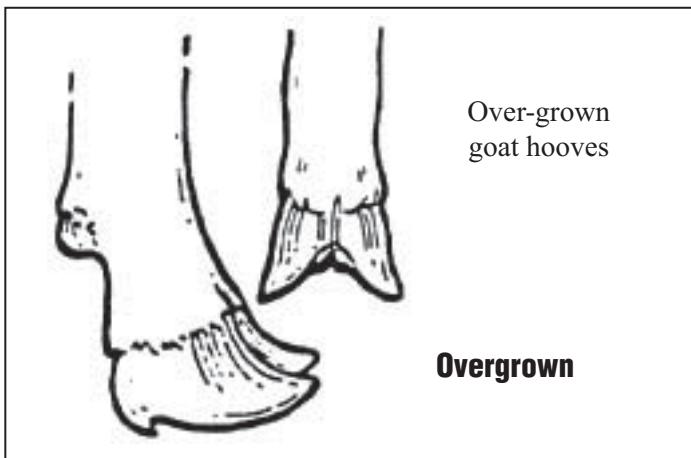


Figure 5. This picture originally appeared in *Goat Rancher* magazine, in an article entitled "Healthy Feet are vital to Caprine Health," by Suzanna W. Gasparotto

Common Problems

While good maintenance can help eliminate lameness problems, there is always some chance that an animal will contract a disease or develop a condition that must be treated. There is a vast array of maladies of the hoof that can range from simple infections that are easily cured to an incurable problem leading to permanent hoof damage and possible culling or euthanizing. In the following section, a few of the most common hoof problems in key species will be discussed. These diseases and problems will be

discussed by species in order to minimize confusion. Many diseases may have different names, but are very similar across different species.

Cattle

The majority of hoof problems in the bovine species affect dairy cows. Aside from direct injury to the hoof, including punctures, ulcers, abscesses, and lacerations, laminitis is the most common non-infectious lameness in cattle. Laminitis can also cause many other problems in the hoof that otherwise would only occur from direct injury. Hairy heel warts and foot rot also produce large numbers of lame dairy cows each year.

Laminitis is, as its name implies, inflammation of the laminar tissue. This disease, which affects all ruminants, as well as horses, is referred to as founder when it becomes chronic. Laminar tissue, or the laminae, is the sensitive connective tissue that holds the pedal bone to the wall of the hoof. When the tissue swells, it puts pressure on the wall, and cuts off the circulation in the blood vessels of the corium so that the laminae become starved for blood, oxygen, and nutrients. As the tissues die, the bond that holds the pedal bone to the hoof wall weakens, and the bone begins to separate from the wall. With less support, and a weaker bond to the wall, the pedal bone begins to pull from the deep flexor tendon and rotates in the hoof. Hooves that are afflicted with laminitis also begin to grow at abnormal rates due to increased vascularization, altering the shape of the hoof and adding more discomfort to the animal. The chronic condition of laminitis is then called founder.

In cattle, laminitis itself is not nearly as detrimental as the side effects that it produces. Although laminitis will produce lame cattle, the other hoof problems that develop as side effects of laminitis are usually more severe. Laminitis in cattle results from dysfunction of the blood vessels serving the laminae and from softening of the ligaments of the suspensory apparatus leading to rotation of the pedal bone and compression of the digital cushion. This causes hemorrhages in the sole, as well as formation of lower quality horn in the hoof. When the bone begins to separate from the wall, it can cause the sole to separate from the wall at the white line, a disease known as white line disease. If the white line pulls too far away from the sole it can open the hoof up to infections. Laminitis can also lead to problems such as solar abscesses, and a condition known as under run heels, which results from the excessive overgrowth of the toe (**See Figure 6**).

Although the exact causes of laminitis are not certain, it is generally accepted that the primary cause of laminitis in cows is rumen acidosis. Acidosis results either from a diet that contains too much starch or one that does not contain



Figure 6. An overgrown bovine hoof due to laminitis

enough fiber. Starch in the rumen is broken down and produces lactic acid. When acidosis occurs, the level of lactic acid exceeds the capacity of rumen microbes to metabolize it. The increase in acidity can kill populations of rumen microbes and this is thought to release toxins which are responsible for changes in the foot. Since the diet is a key trigger of laminitis, changing a cow's ration is necessary if a cow develops laminitis. Also, a regular trimming and maintenance program will be needed on hooves of animals with laminitis. After an episode of laminitis, the hoof will not grow normally at the toe again, and must be kept well-trimmed in order to ensure that it retains its shape, as well as provide proper weight-bearing surfaces.

Dairy cattle can also get a condition called *Papillomatous Interdigital Dermatitis*, commonly known as hairy heel warts. Hairy heel warts or interdigital dermatitis is an infection that occurs mostly in dairy cows, producing inflamed, red lesions on the interdigital skin of the hoof (See Figure 7). Hairy heel warts are thought to be caused by strains of the anaerobic bacteria *Treponema*. These bacteria thrive in muddy, dirty, and damp conditions. When foot warts are observed, the best way to treat them is with a footbath or a topical spray containing several remedies. Antibiotics such as oxytetracycline or lincomycin are preferred by many veterinarians, although some people still choose to use formalin as a treatment for foot warts. Formalin use is highly discouraged due to the carcinogenic properties of the chemical. Some producers choose to apply a powder form of one of the antibiotics and wrap the feet of animals afflicted with heel warts, but this may be too time-consuming for large dairy operations. Cleaning the aisles and stalls of the cow barn will also help to alleviate the problems that the manure and mud can cause to the hoof, and prevent further infections of heel warts.

The last bovine hoof disease that will be discussed is hoof rot. Hoof rot in cattle is caused by the bacteria

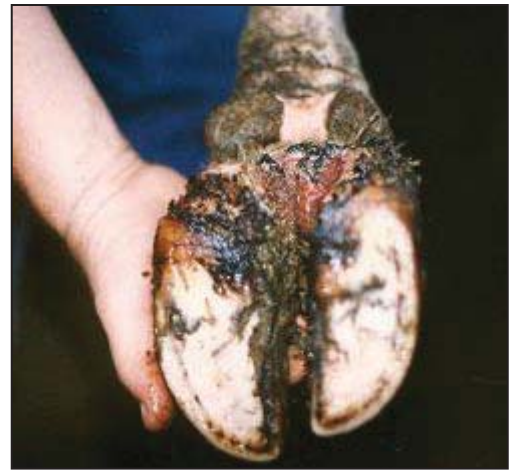

Figure 7. Hairy heel warts in cattle

Photo courtesy of Dr. Simon Kenyon

Fusobacterium necophorum. These are anaerobic bacteria that thrive in muddy, damp conditions. Hoof rot can be characterized by a variety of symptoms. The animal will most likely exhibit some degree of lameness. Other symptoms may include a foul smelling discharge, reddened tissue above the hoof, and possibly swelling of the hoof and spreading of the toes (See Figure 8). Treatment for hoof rot in dairy cattle consists of treatment with systemic antibiotics that will not interfere with milking and do not have a milk withdrawal time. The key to treating and preventing hoof rot in cattle is by keeping the living quarters as clean as possible, by regular hoof trimming, and through the use of footbaths. Typically, copper sulfate is used in footbaths to harden the hoof and adjacent tissue, making it more difficult for bacterial infection to become established. Oral feeding of increase levels of biotin and zinc may harden the hoof tissue as well.

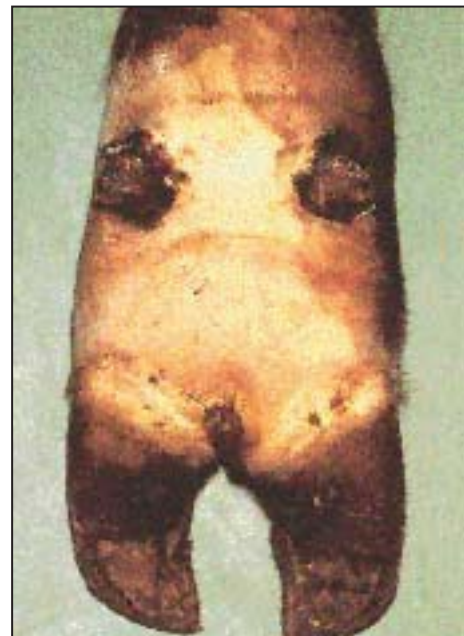

Figure 8. Hoof rot in cattle

Photo courtesy of Barry Stevens, State Extension Dairy Specialist, University of Missouri

Horses

It may sound cliché to quote the age old saying, “no hoof, no horse,” but it is entirely too true. Although horses are no longer used as a primary mode of transportation in the United States, their main use is still for riding or other athletic endeavors, and a riding horse must have sound, healthy hooves in order to function properly and be of any use to its owner.

Horse’s hooves can require more maintenance than dairy hooves, or the hooves of any other animal for that matter, depending on their athletic use. As mentioned previously, horse’s hooves not only require daily cleaning, but some horses benefit from shoeing as well. Horse’s hooves are subjected to many insults either out in the pasture or while they are being ridden or driven. Stone bruises, punctures, and abscesses are all common problems in equine hooves. Horses also suffer from diseases similar to those in cattle, sheep, and goats.

Horses, like cattle, suffer from a disease called laminitis. Laminitis in horses occurs in the same general way as cattle; however, the cause of and the effects of it are somewhat different in a horse than they are in the bovine hoof. Although the specific cause of equine laminitis has not been entirely determined, there are a few commonly accepted triggers for an episode of laminitis. Horses that eat an excessive amount of grain at one time, such as a horse that got loose and gorged itself in the grain bin, are very susceptible to laminitis. Laminitis can also be caused by sudden changes in available carbohydrate in the diet, particularly when turning horses out in lush pasture in the spring. Excessive work on a hard surface or long trailer rides without adequate bedding or cushion can cause “road” or “mechanical founder”.

When an episode of laminitis occurs in a horse, similar events occur inside the hoof that occurs in a bovine hoof. The laminae swell and separate allowing the coffin bone to pull away from the hoof wall. In horses, however, the biggest problem that they experience is from the laminitis itself, not a side-effect of the disease. In very severe cases of founder (as laminitis is often called in horses), the coffin bone can actually rotate through the bottom of the sole, causing the animal immense amounts of pain. It can open the foot up to a wide variety of infection.

When a horse develops laminitis, it will likely exhibit the typical “laminitis stance.” (See **Figure 9**) When this happens, the animal shifts the majority of its weight to the rear legs and walks very gingerly, if at all. When laminitis is first diagnosed, a veterinarian may give the animal anti-inflammatory drugs, and possibly tranquilizers to reduce the swelling of the tissue, and to prevent further damage. If the animal has overeaten, and thus at high risk



Photo courtesy of Christopher C. Pollitt, BVSc, PhD.

Figure 9. Typical “laminitis stance” in horses

for a case of founder, the meal can be moved through the body with laxatives and cold water applied to the hooves. When an episode of laminitis is caught early, there is a good chance of recovery. However, when it goes unnoticed, hoof damage continues to develop, leading to the need for more drastic treatment. For mild cases, stall rest on thick bases of wet sand may be enough. In more severe cases of founder, corrective shoeing and (or) surgery may be necessary. No matter what the severity of the episode, the horse will be out of commission for quite sometime and should be watched closely for any signs of a recurrence. Once a horse has had laminitis, and especially if it becomes founder, it will be much more susceptible to consequent episodes and should be kept in a low risk environment.

The most common infection in equine hooves is thrush. Thrush is somewhat similar to foot rot in ruminants in that an anaerobic bacteria infects crevices of the hoof and begins to degrade it. Thrush is caused primarily by the bacteria *Spherophorus neophorus* that thrives in wet and unsanitary conditions. This bacteria invades the grooves on either side of the frog and begins to eat away at it, causing a gooey, black discharge in the frog that is often followed by lameness and inflammation.

Thrush is a good indicator that the living quarters of one’s horse are not as well-maintained as they should be. Severe cases of thrush can cause serious lameness, but most cases can be cured within a week or two.

Thrush can be treated in a variety of ways. First and foremost, the animal’s living conditions should be examined, and the horse’s stall should be made as clean and dry as possible so as to eliminate the environment that promotes thrush. Regular cleaning of the horse’s hooves will also help to get rid of thrush and prevent further episodes. Many commercial topical products are available to treat thrush, but many veterinarians will say that a

dilute bleach or hydrogen peroxide solution will be just as effective in getting rid of thrush.

Sheep and Goats

Sheep and goats are very similar in their anatomy, so they will be discussed together. The main affliction of hooves in sheep and goats is foot rot. The foot rot that affects sheep is caused by bacteria different from those that cause bovine foot rot or equine thrush. Foot rot in sheep and goats is caused by an anaerobic bacterium called *Bacterioides nodusus*. Foot rot can be characterized by a variety of symptoms. The animal will most likely exhibit some degree of lameness. Other symptoms may include a foul smelling discharge, reddened tissue above the hoof, and possibly swelling of the hoof and spreading of the toes.

When foot rot does occur, there are a few key elements necessary to eliminate it. First, infected animals must be isolated from the herd to stop the foot rot from spreading. The feet of infected animals must then be trimmed to expose the infected areas so that it can drain, dry out, and heal. Topical sprays or foot baths containing drying agents, such as zinc sulfate, can be used to treat foot rot. There is actually a vaccine available for the prevention of hoof rot; however, it will be of no use if the other aspects of proper care and maintenance are overlooked. The best way to deal with foot rot is to maintain conditions where foot rot can not exist, thus eliminating the economic losses that a bout of foot rot can cause.

The best way to control foot rot is to prevent it. Animals from a herd that has foot rot, or that are exhibiting symptoms of foot rot themselves, should not be introduced into a herd that is free of foot rot. New animals should be quarantined as a precautionary measure so as to prevent the herd from becoming infected. Aside from this, minimizing muddy and moist conditions and keeping hooves trimmed regularly will minimize the possibility that foot rot will have a chance to flourish.

Summary

The hoof is a complex structure that plays a key role in many aspects of the animal's overall health and productivity. Healthy hooves lead to healthy animals, which raises productivity and income. When hooves are kept in good condition, it reduces the losses that stem from treating lame animals and the production losses that result from their discomfort. A lame animal is not only in pain, but it is an extra expense that most producers can not afford. By maintaining a sound hoof management routine, animal owners can reduce their economic losses and increase their chances for profit in the future.

Glossary of Terms

Abaxial surface: The outside portion of each claw. The abaxial surface is the area that is plainly visible when an animal is standing or moving.

Abscess: A localized infection inside the hoof tissue that can cause lameness and requires drainage in order to prevent rupture at the hoof head.

Axial surface: The part of each claw that is on the inside. The axial surfaces of claws on one hoof face each other.

Cloven hoof: A hoof, like that of a cow, sheep, or goat, that consists of two claws.

Claw: The two separate digits (toes) of a cloven hoof.

Coffin bone: The same as a pedal bone in cloven-hoofed animals, except that a horse only has one

Coronary region: The region at the top of the hoof, where the new growth comes out.

Corium: The part of the hoof that produces the new hoof growth. It contains many nutrients and blood vessels that are necessary to produce new hoof growth, as well as a lot of nerves, which makes it very sensitive. It is very much like the quick of the human fingernail.

Dew Claw: The accessory toe at the back of the hoof that serves no function.

Frog: The V-shaped region of a horse's sole. It serves as a shock absorber and as a mechanism to pump blood up through the horse's leg.

Foot rot: A bacterial infection that occurs most commonly in sheep and cows. It is caused by bacteria that thrive and grow in conditions lacking air circulation and oxygen, such as the hoof of animal standing for long periods of time in mud and manure.

Founder: The chronic form of laminitis.

Hairy heel warts: An infection of the skin between the two claws of the hoof. It occurs mainly in cattle, produces inflamed red sores in the interdigital skin of the hoof. Also called "strawberry warts".

Hoof rot: A bacterial infection that occurs in the hoof of cattle, sheep, and goats.

Hoof wall: The hard outer layer of the hoof, similar to a human fingernail, can also be called the hoof horn.

Horn: Another name for the hard, outer covering of the hoof, also known as the hoof wall.

Interdigital cleft: The space between the two claws of a cloven-hoofed animal.

Interdigital skin: The piece of skin that is between the two claws of a cloven-hoofed animal.

Laminae: The sensitive tissue inside the hoof that connects the pedal bone to the corium.

Laminitis: A non-infectious disease of the hoof that can affect any hoofed animal. It is characterized by lameness, and excessive growth of the hoof, and can range in severity from mild to very severe and chronic.

Pedal bone: The largest bone inside the hoof. The main shape of the hoof is determined by the shape of the pedal bone.

Periopic horn: The soft, new hoof growth that exists in the coronary region.

Sole: The bottom portion of the hoof that the animal actually stands on. It is made of the same type of cells as the hoof wall, only it is slightly softer than the wall.

Sole bruise: The crushing of blood vessels between the hoof horn and the bones on the inside of the hoof, usually caused by an animal stepping on something hard or sharp.

Trimming: The process by which the extra growth of the hoof wall is cut off or filed down, in order to restore the proper shape of the hoof. Frequency of trimming depends on the species in question and the particular conditions that the animal lives in.

White Line: The line around the edge of the sole that is the junction between the sole and the hoof wall on the underside of the hoof.

References

Berry, Steven L. DVM, MPVM. *Hoof Health*. Western Dairy Management Conference, 1999; 14-17.

Berry, Steven L. DVM, MPVM. *The Three Phases of Bovine Laminitis*. Hoof Trimmers Association, Inc. Newsletter, March 2002.

Blowey, Roger. *Cattle Lameness and Hoofcare and Illustrated Guide*. Ipswich United Kingdom: Farming Press Books, 1993.

Burgi, Karl. *Functional and Corrective Hoof Trimming*. Comfort Hoof Care, July 2000.

Fitch, Gerald Q. *Foot Rot Control*. Oklahoma Cooperative Extension Service.

Gasparotto, Suzanne W. HC 70 Box 76, Lohn, TX 76852, Phone 325-344-5775, Fax 325-344-5774

Guard, Chuck. *Give your footbath a chance to work*. Hoard's Dairyman: May 1995, 6-7.

Greenough, Paul R., Laverne M. Schugel DVM, A. Bruce Johnson Ph.D., *Zinpro*

Corporation's Illustrated handbook on Cattle Lameness. USA: Zinpro Corporation, 1996.

International Equine Resource Center *The Farrier and Hoofcare Resource Center*. <<http://www.horseshoes.com>>

Johnson, E.L. *Basic Hoof Care for Horses*. University of Florida Cooperative Extension Services, May 1997.

Kenyon, Simon. *Managing Hairy Warts*. School of Veterinary Medicine, Purdue University.

Roefeldt, Shirley. *How to judge a hoof trim*. Dairy Herd Management, December 2000: 30-36.

Schurg, William A. PhD *What are Sole Bruises?* Arizona Livestock Review Spring 2004:2.

Sustaire, Don, Dr. Doug Householder, Cathy Schwab. *Evaluation of Horse Shoeing*

Techniques. Texas A&M Department of Animal Science Equine Science Program.

Townsend, Jonathan. *Heel Wart Update*. Department of Veterinary Clinical Sciences, Purdue University.

Toussant, Raven E DVM. *Cattle Footcare and Claw Trimming*. Ipswich, United Kingdom: Farming Press Books, 1989.

Volk, Chris. *10 Hoof-Care Tips You Need to Know*. Practical Horseman, August 2000: 89-93.

Wagner, Ilka P, DVM. *Laminitis*. Practical Horseman: May 1999: 90-95.

Watson, Kim. *Seven ways to avoid lameness when expanding*. Dairy Herd Management, November 2000.

Webster, John. *Understanding the Dairy Cow* 2nd Edition. London: Blackwell Scientific Publication, 1993.



PURDUE AGRICULTURE

10/04

It is the policy of the Purdue University Cooperative Extension Service, David C. Petritz, Director, that all persons shall have equal opportunity and access to the programs and facilities without regard to race, color, sex, religion, national origin, age, marital status, parental status, sexual orientation, or disability. Purdue University is an Affirmative Action employer. This material may be available in alternative formats.

1-888-EXT-INFO

<http://www.ces.purdue.edu/new>

Purdue Extension
Knowledge to Go
1-888-EXT-INFO